

HEMOENCEPHALOGRAPHY TRAINING – AN EFFECTIVE METHOD FOR IMPROVING BRAIN FUNCTION

PART 1. THEORETICAL ASSUMPTIONS OF THE METHOD

ANDRZEJ BARTOSIŃSKI¹, WANDA STANKIEWICZ¹,
KRYSTYNA ZIENIUK², MAŁGORZATA KIEŁCZEWSKA¹

¹ *Laboratory of Psychoneuroimmunology, Department of Microwave Protection
Military Institute of Hygiene and Epidemiology, Warsaw, Poland*

² *Military Institute of Medicine, Warsaw, Poland*

E-mail: andrzej.bartosinski@wihe.pl

Abstract: Biofeedback is a method that uses specialized equipment and software to reflect psychophysiological processes and their alterations. The basic method for assessing brain efficiency and its changes is electroencephalography (EEG). Hemoencephalography as a method of biofeedback training has several advantages over an EEG application. The authors use EEG to evaluate the effects of hemoencephalography training.

Key words: biofeedback, neurofeedback, EEG, HEG

DOI: 10.34668/PJAS.2018.4.3.06

Introduction

The origins of research on the brain's electrical activity can be traced back to the end of the nineteenth century and the beginning of the twentieth century. It is worth mentioning three of many researchers included two Poles: Napoleon Nikodem Cybulski (1854-1919), Adolf Beck (1854-1919) and a German, Hans Berger (1873-1941). In 1890 Cybulski accomplished one of the first-ever EEG recordings of the cerebral cortex. Working with Adolf Beck, he performed pioneering research on electroencephalographic waves. Under Cybulski's supervision, Beck made pioneering studies of cerebral-cortex activity in response to peripheral-nerve stimulation in dogs and monkeys, using electrodes placed on the skull to record changes in electric potential. Berger was the first to recorded alpha waves [1,2]. Biofeedback as a science was born in the 1960s. Biofeedback is a method that uses specialized equipment and software to reflect psychophysiological processes and their modification. Biofeedback provides constant and immediate information e.g. about brain waves, heart rhythm, respiratory rate, body temperature, the impedance of the skin, and blood pressure. In cooperation with a physician and a psychologist (generally a therapist) a person is subjected to the biofeedback procedure, focusing on performing a task which modifies his or her own psychophysiological processes. Neurofeedback as a method of improving the brain is important in health and disease treatments. The list of neurofeedback applications is long (The list was published by the International Society for Neuronal Regulation. The list contains literature items on specific issues [3]) and contains, among others:

- ADD (Attention Deficit Disorder) /ADHD (Attention-Deficit Hyperactivity Disorder),
- Depression & Hemispheric Asymmetry,
- Addiction Disorders,
- Post-Traumatic Stress Disorder,
- Pain and Headache,
- Schizophrenia,
- Traumatic Brain Injury, Stroke, Coma, & Cerebral Palsy,
- Obsessive Compulsive Disorder,
- Autism & Asperger's.

The use of neurofeedback in healthy people include:

- Cognitive Enhancement,
- Optimal Functioning and Peak Performance (e.g.: golf performance enhancement, musical performance, dance performance).

Neurofeedback

Neurofeedback also known as encephalography-biofeedback or EEG-biofeedback is a type of biofeedback that uses an encephalograph and a computer with dedicated software. The development of neurofeedback was possible due to the enormous progress in the field of electronics (signal acquisition and processing) and the application of advanced mathematical calculations and their computer applications. These achievements have lead to the transformation of EEG patterns into images on a computer screen. The essence of neurofeedback is learning to influence these images and thereby self-regulating the EEG (and what is the self-regulation of a complex, dynamically changing nervous system). Hemoencephalography training can be considered as a simplified version of neurofeedback.

- Epilepsy,

Electroencephalography (EEG)

Electroencephalography is one of the most important diagnostic methods that allows for the visualization of the electrical signals generated by the brain [4]. EEG reflects the resultant electrical activity of the brain (and in particular the cerebral cortex) at any given moment. This activity is related to all processes in which the brain is involved. These processes can be:

- planning,
- thinking,
- remembering or learning,
- receipt of stimuli, their analysis,
- making decisions about reactions or directing attention.

The above activities overlap the activity of the cerebral cortex associated with continuous processes, regardless of our awareness:

- managing the functioning of the digestive system,
- coordination of complex movements,
- respiration.

A record of brain activity is additionally complicated by spontaneous neuron discharges (when they are not stimulated by other neurons) [5]. There are two basic areas of electroencephalography, namely the study of the spontaneous electrical activity of the brain and the study of evoked potentials. Wave frequency is measured in Hertz (Hz), while their amplitude is measured in microvolts (μV). Spontaneous brain activity (basic), i.e. cortical activity induced by continuous brain operation, without external triggering stimuli, are waves (rhythms) of different frequency: in the range of 0.5 – 60 Hz and amplitude: 5 – 400 μV . The working brain produces slow moving electric waves that flow at a regular rate through the cerebral cortex. The brain produces 5 basic waves, of which four bands are produced continuously (delta, theta, alpha and beta) and a gamma wave, which is a non-permanent band. Each of the brain bands has its own characteristics [4, 6, 7]:

Delta has a range of values from 0.5 to 3.9 Hz (amplitude: 20 – 30 μV) and belongs to slow waves. Delta waves appear during deep sleep (Non-rapid eye movement, NREM), often treated in the EEG as an artefact. Delta waves may appear in a small child during waking, but it is recognized that they should never appear in the normal EEG record of an adult in waking condition – their presence is a sign of brain dysfunction (thanks to research conducted in the mid-1930s by English physiologist W. Gray Walter, it is known that the focal occurrence of delta waves indicates brain damage [8]). Delta waves may occur (in small amounts) in the elderly, in the temporal area and may be due

to vasogenic changes. Incorrect delta waves may cause neurological and/or psychological diseases. The diffused delta waves most often indicate total brain damage, whereas their high amplitude may indicate severe central nervous system (CNS) dysfunction.

Theta is also slow wave, and its frequency range is from 4 to 7.9 Hz (amplitude: 10 – 15 μV) (Fig. 1). Theta waves

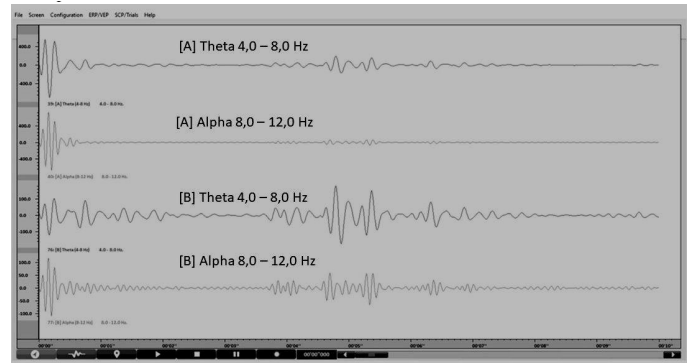


Fig. 1: Visualization of brain waves: theta and alpha. Electrode assembly 10-20, A – left hemisphere, B – right hemisphere, software BioTrace. Own research.

occur during the wakefulness of an adult, during the feeling of relaxation (also during meditation or under the influence of hypnosis), in people who do not feel fear, are sleepy, feel hungry or have a high fever; these are also present (same as the delta band) during wakefulness in young children, often treated in EEG as artefacts. However, theta waves may also be completely absent from the EEG record. In the brain, they are responsible for the creative area, increase endorphins and an increase the body's resistance. The highest amplitude of theta rhythm can be observed along the leads from the midline of the brain (along with the part of the great ventricle) and in the temporal region. Theta waves, in the correct EEG record, are symmetrical. The pathological occurrence of theta waves (the same as in the case of delta waves – not rhythmically, or in the areas of the brain where they do not usually occur) may result in significant cognitive dysfunctions – mainly a decrease in mental attention, disability and increased occurrence of neurological diseases. In addition, observing the theta rhythm in only one location or if they dominate only one hemisphere, indicates a fairly high probability for structural damage of the brain (stroke, gliomas, meningiomas). During a coma after a severe brain injury, the theta band may occur in the frontal area, and with this there is never a good prognosis. Theta fuzzy waves are observed mostly in children.

Alpha is included in the group of fast waves, and its frequency ranges from 8 to 12.9 Hz (amplitude: 8 – 15 μV) (Fig. 1). This is the main, basic wave in the normal adult EEG record. It can be seen in the EEG record when a person feels a very deep relaxation, drowsiness or boredom,

and passive attention. In the wakefulness of adults, alpha waves appear only with closed eyes. Alpha rhythm is responsible for better memory, positive thinking, release from stress. The highest amplitude of the alpha rhythm is observed in the occipital region – in a properly functioning brain it appears with closed eyes and disappears when the eyes are open. It is called the dominant wave in the back area of the head. It also appears in other locations in the brain (adjacent posterior and parietal temporal areas), but has a much lower amplitude then; in very rare cases, you may also notice weak alpha activity in the frontal area of completely healthy people. The alpha activity is usually symmetrical, but its higher amplitude over the non-dominant hemisphere is more frequently observed – as long as the ratio of alpha amplitude does not exceed the ratio of 2: 1 it is considered normal; if it exceeds such a proportion, it should be looked at in the direction of pathological processes that can take place in the brain. Alpha waves may also occur in a pathological way – keeping the alpha rhythm with the eyes open may result from increased drowsiness of the examined person, but this state is also observed in patients with dementia, depression or in disorders of concentration. In addition, alpha rhythm may also be affected by drugs (especially phenytoin, psychotropic drugs), alcoholism, dementia (including initial phases), thyroid disease (mainly hypothyroidism), increased intracranial pressure and various metabolic disorders.

Beta waves also belong to fast waves, and their frequency ranges from 12 to 35 Hz. Beta waves are also rhythmic, and their highest amplitude is recorded in the central – frontal regions (although they can also be observed in other parts of the head). Beta waves are not sensitive to the open or closed state of the eyes, but it should be noted that in the drowsiness phase they tend to increase their amplitude (with simultaneous lowering the amplitudes of other brain waves). The increase in beta waves in the EEG record may result from the use of drugs (e.g. barbiturates, benzodiazepines, tricyclic antidepressants, or chloral hydrate). Since the beta rhythm is the most common rhythm in the EEG record, sometimes difficulties arise in its correct interpretation, but it should be noted that it is quite symmetrical. In the asymmetry of the hemispheric beta waves – where the amplitude is lower – a disease process is often observed (e.g. stroke, porencephaly or subdural fluid collection), in turn, if we are dealing with a higher than normal beta amplitude, this may indicate that the subject has undergone craniotomy or the brain tumor may be growing directly below the site of amplitude increase. When discussing beta waves, it is worth noting that their high amplitude causes high energy consumption in the body, which can lead to high load and fatigue. The beta wave family is divided into the following three bands:

SMR sensory motor rhythm (called sensorimotor rhythm) (frequency from 12 to 15 Hz, amplitude: 4 – 6 μ V). They appear during wakefulness, as well as in a state of relaxation with a focus on external stimuli. The SMR band is responsible for the control of anxiety and anger and for better sleep and body awareness. The occurrence of SMR waves in a negative way most often occurs in people with ADHD, autism spectrum disorders and, in general, in overactive people.

Beta 1 (frequency from 15 to 18 – 19 Hz, amplitude: 3 – 4 μ V). They occur during activity, also with attention focused on external stimuli; while thinking, focusing attention, keeping pace in motion, action, or physical activity. An incorrect occurrence of beta-1 (e.g. in a non-rhythmic way) is observed during depression, with the lack of attention or at a very slow pace of work.

Beta 2 (frequency from 20 – 22 to 35 Hz, amplitude: 6 – 10 μ V). They become visible during the feeling of very intense emotions (above all negative ones) – irritation, anger, stress, anxiety, nervousness, or rage. The increased amplitude of beta 2 rhythm can be noticed during the experience of intense stress and negative emotions with (fear, anxiety, anger, or stage fright).

Gamma, which is a non-constant band, has a range of frequency values from 30 – 35 to 200 Hz (whereby the amplitude fluctuations of this band are very large). They may appear during extreme experiences, while their total absence is observed in people suffering from schizophrenia.

HEG

Transcranial hemoencephalography – a method that allows local changes in hemoglobin concentration to be measured. This method was introduced by H. Toomim in 1999 [9–11]. Near-infrared hemoencephalography, abbreviated as NIR-HEG, is a noninvasive measurement of the level of local tissue saturation with oxygen, corresponding to changes in hemodynamic flow and changes in tissue metabolic activity [12]. The advantages of this method are excellent time resolution, the possibility of continuous observation of hemodynamic changes, significantly lower costs compared to functional Magnetic Resonance Imaging (fMRI) and resistance to artifacts associated with the subject's movements [13]. The hemoencephalography method is cheaper and simpler than the EEG application. In many therapeutic applications, hemoencephalography exceeds electroencephalography and works when improving the brain.

EEG analysis

For the analysis of the EEG signal the LORETA application (Low Resolution Brain Electromagnetic Tomogra-

phy) is used [14]. LORETA software allows for the visualization of the brain structures by using the recorded EEG signal [15]. Mapping the charge distribution in the brain based on knowledge of tensions in the head is a classic inverse problem. This is a task that often occurs in various branches of science, where some parameters of the model must be determined based on the observed values. It should be noted that LORETA is very complex and requires a significant amount of work to master (both knowledge of the program itself and knowledge of the anatomy and functioning of the brain). Application sLORETA (standardized Low Resolution Brain Electromagnetic Tomography) is a modified version of the LORETA program [14,16]. The software separates both the basic division of the brain into fields (developed at the beginning of the twentieth century by Korbinian Brodmann) (Fig. 2), and also the coplanar,

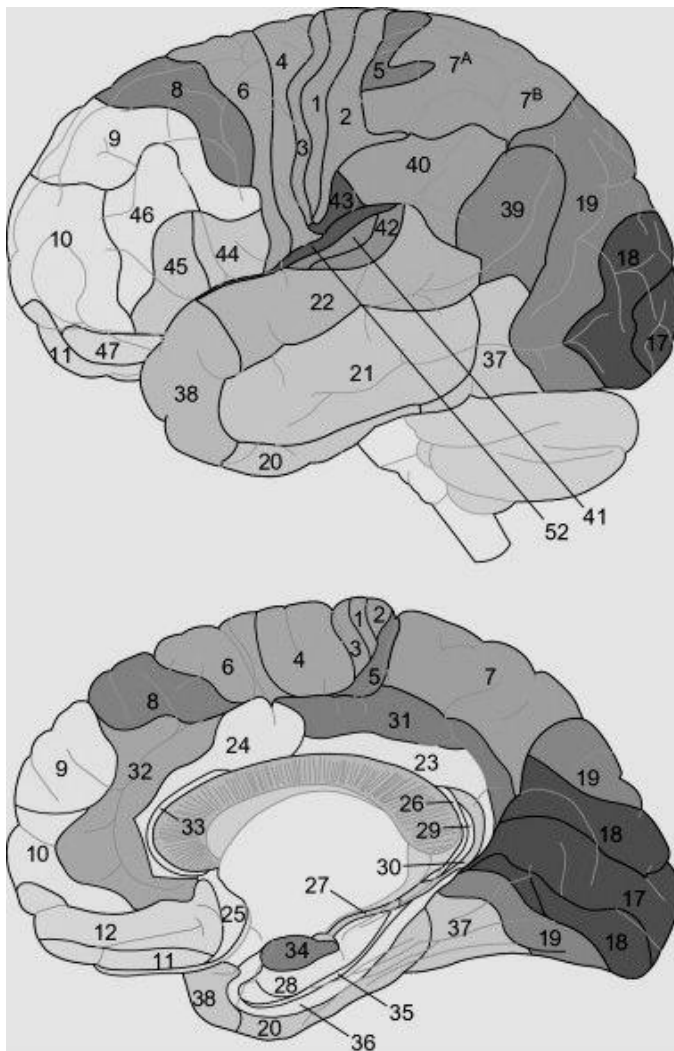


Fig. 2: Brodmann areas [17].

stereotactic atlas of the human brain developed by Jean Talairach and Pierre Tournoux. [18]. The techniques divide

the brain into small cubes of equal volume (voxels) (Fig. 3). This analysis is used to assess the spontaneous and functional brain activity. It was used to evaluate the effectiveness of hemoencephalography training. The results are presented in the second part of the article.



Fig. 3: The idea of creating human brain voxels [19].

Summary

EEG and hemoencephalography is used to assess brain function. Changes in the processed EEG record such as spectral entropy, relative power, and distribution of electrical charge density can evaluate the effects of hemoencephalography training. The changes in their value can be evaluated using the solution of the inverse problem (sLORETA) applied to the 21-channel EEG recording before and after hemoencephalography training.

Literature

- [1] Kułak W., Sobaniec W. Historia odkrycia EEG. *Neurologia Dziecięca*, 15/2006:4, 2006.
- [2] Sanei S., Chambers J.A. *EEG signal processing*. John Wiley & Sons, 2013.
- [3] Hammond D.C. *Comprehensive Neurofeedback Bibliography*. 2009.
- [4] Rowan A., Tolunsky E., Sobieszek A. *Podstawy EEG z miniatlasem*. Elsevier Urban & Partner, Wrocław, 2004.
- [5] Jaśkowski P. *Zarys psychofizjologii*. Wydawnictwo Wyższej Szkoły Finansów i Zarządzania, Warszawa, 2004.
- [6] Pakszys M. *Neurologia i Neurofizjologia. Materiały szkoleniowe*. EEG Instytut, Warszawa, 2018.

- [7] Pakszys M. *REPETYTORIUM II. Materiały szkoleniowe*. EEG Instytut, Warszawa, 2018.
- [8] Amzica F., Steriade M. Electrophysiological correlates of sleep delta waves1. *Electroencephalography and clinical neurophysiology*, 107(2):69–83, 1998.
- [9] Toomim H. et al. Intentional increase of cerebral blood oxygenation using hemoencephalography (HEG): An efficient brain exercise therapy. *Journal of Neurotherapy*, 8(3):5–21, 2005.
- [10] Siever D. History of Biofeedback and Neurofeedback. *Biofeedback*, 2008.
- [11] Toomim H., Carmen J. *Introduction to quantitative EEG and neurofeedback: Advanced theory and applications 2nd ed.*, chapter Hemoencephalography: Photon-based blood flow neurofeedback., pages 169–194. 2009.
- [12] Serra-Sala M., Timoneda-Gallart C., Pérez-Álvarez F. Evaluating prefrontal activation and its relationship with cognitive and emotional processes by means of hemoencephalography (HEG). *Journal of Neurotherapy*, 16(3):183–195, 2012.
- [13] Coben R., Padolsky I. Infrared imaging and neurofeedback: Initial reliability and validity. *Journal of Neurotherapy*, 11(3):3–13, 2008.
- [14] Pascual-Marqui R.D. et al. Functional imaging with low-resolution brain electromagnetic tomography (LORETA): a review. *Methods and findings in experimental and clinical pharmacology*, 24(Suppl C):91–95, 2002.
- [15] Pascual-Marqui R.D. Standardized low-resolution brain electromagnetic tomography (sLORETA): technical details. *Methods Find Exp Clin Pharmacol*, 24(Suppl D):5–12, 2002.
- [16] Pascual-Marqui R. et al. Functional imaging with low resolution brain electromagnetic tomography (LORETA): review, new comparisons, and new validation. *Japanese Journal of Clinical Neurophysiology*, 30:81–94, 2002.
- [17] Baars B.J., Gage N.M. *Cognition, brain, and consciousness: Introduction to cognitive neuroscience*. Academic Press, 2010.
- [18] Talairach J., Tournoux P. *Co-planar stereotaxic atlas of the human brain. 3-Dimensional proportional system: an approach to cerebral imaging*. 1988.
- [19] www.dreamstime.com/stock-illustration-voxel-human-brain-d-render-isolated-white-background-image51834849 Access 09.11.2017.

Received: 2018

Accepted: 2018